

# **CANCER**

## **ARISING FROM ENDOMETRIOSIS: CLINICAL IMPLICATIONS**

**Farr R. Nezhat, MD, FACOG, FACS**

**Professor, Department of Obstetrics, Gynecology & Reproductive Science**

**Icahn School of Medicine at Mount Sinai**

**Director, Division of Minimally Invasive Gynecologic Surgery & Robotics**

**Department of Obstetrics & Gynecology, Division of Gynecologic Oncology**

**Mount Sinai St. Luke's and Roosevelt**

**Adjunct Professor, Department of Obstetrics, Gynecology & Reproductive Medicine**

**State University of New York at Stony Brook, School of Medicine**

**Director, Division of Minimally Invasive Gynecologic Surgery**

**Department of Obstetrics & Gynecology**

**Winthrop University Hospital**

**New York, NY**

**NO DISCLOSURE**

# Publications

- 1) Nezhat F, Cohen C, Rahaman J, Gretz H, Cole P, Kalir T. **Comparative immunohistochemical studies of bcl-2 and p53 proteins in benign and malignant ovarian endometriotic cysts.** Cancer 2002;94(11):2935-40.
- 2) Nezhat F, Datta MS, Hanson V, Pejovic T, Nezhat C, Nezhat C. **The relationship of endometriosis and ovarian malignancy: a review.** Fertil Steril 2008;90(5):1559-70.
- 3) Nezhat FR, Pejovic T, Reis FM, Guo SW. **The link between endometriosis and ovarian cancer: clinical implications.** Int J Gynecol Cancer 2014;24(4):623-8.
- 4) Nezhat FR, Apostol R, Mahmoud M, El Daouk M. **Malignant transformation of endometriosis and its clinical significance.** Fertil Steril 2014 [*In Press*]

# Case Presentation

- ◆ The patient is a 29yo P0 who was found to have a left **2.6x3.6cm** ovarian cyst(dermoid vs endometrioma) during her evaluation for infertility for one year.
- ◆ Ob/Gyn History: Para 0, **regular mestural cycles**, mild dysmenorrhea, .Not obese or over weight . Denies any STDs or pelvic infections.
- ◆ No Past Medical or Surgical

# Case Presentation

- ◆ She had laparoscopy, left ovarian cystectomy for a presumed dermoid cyst, and dilation and curettage.
- ◆ Laparoscopy: Pelvic endometriosis.
- ◆ Pathology
  - ◆ Left Ovarian Cyst: Well-differentiated endometrioid adenocarcinoma
  - ◆ Endometrial Curettings: Proliferative Endometrium, polypoid fragments of endometrium with complex endometrial hyperplasia with marked atypia

# Case Presentation

- ◆ After consulted with Gyn Oncologist and Neg. Metastatic W/U
- ◆ Laparoscopic Robotic assisted surgical staging followed by chemotherapy, Taxol&Carb.
- ◆ Successful Spontaneous pregnancy x 2
- ◆ NED X4 Years.

# Objectives

- ◆ **Overview of endometriosis and ovarian cancer**
- ◆ **Pathogenesis of malignant transformation of endometriosis**
- ◆ **Clinical applications**
- ◆ **Future investigation**

# Ovarian Cancer in Women with Endometriosis

The malignant transformation of endometriosis was first suggested by Sampson in 1925

*Sampson JA. Endometrial carcinoma of ovary arising in endometrial tissue in that organ. Arch Surg 1925;10:1-72*



# Ovarian Cancer in Women with Endometriosis

- ◆ Epidemiological, Histological and Molecular studies suggested a link between endometriosis and invasive epithelial ovarian cancer, based on frequent co-occurrence in surgical specimens, particularly the histological subgroups endometrioid and clear cell ovarian carcinoma

Nezhat F, Datta MS, Hanson V, Pejovic T, Nezhat C, Nezhat C. The relationship of endometriosis and ovarian malignancy: a review. *Fertil Steril*. 2008;90(5):1559-70

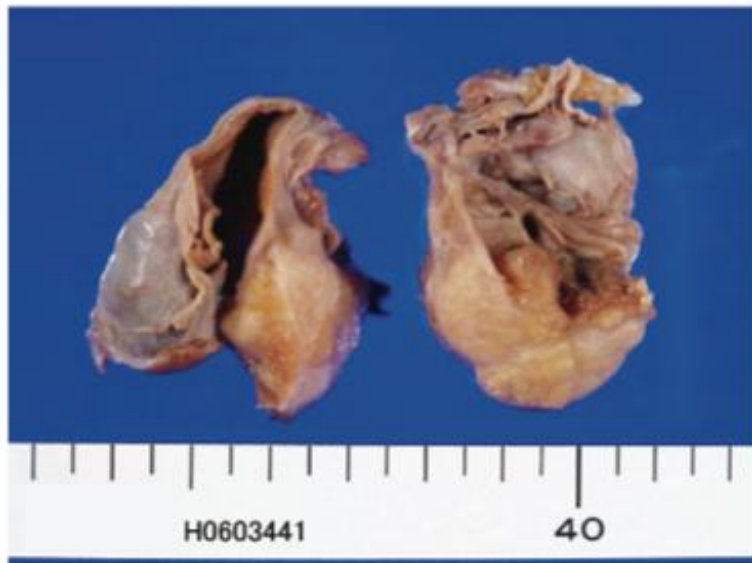Pearce CL *et al*, *Lancet Oncol* 2012;13:385–394

Sayasneh A *et al*., *Obstet Gynecol* 2011;2011:1403–1410.

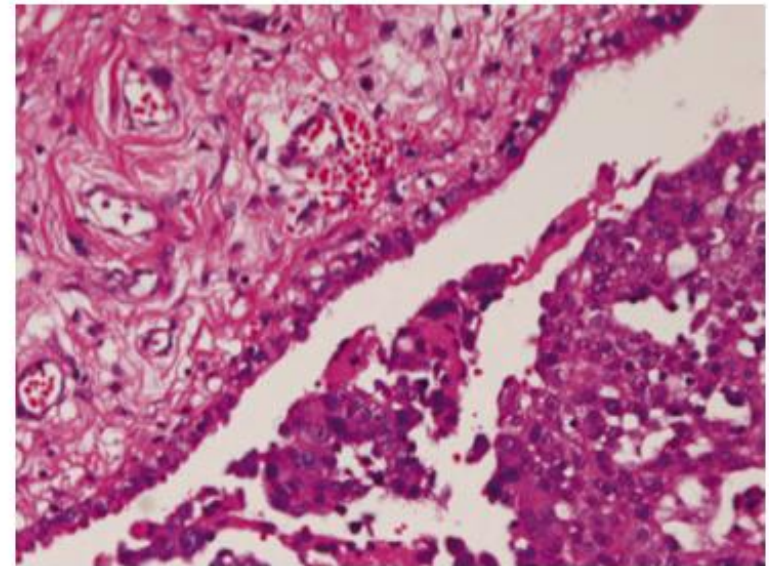
Kim HS, Kim TH, Chung HH, Song YS. Risk and prognosis of ovarian cancer in women with endometriosis: a meta-analysis. *Br J Cancer*. 2014 Feb 11

# Overview of endometriosis and ovarian cancer

## Carcinoma in endometriosis



**Figure 1.** Gross features of endometrioid adenocarcinoma associated with endometriosis of the ovary. A unilocular cyst contain inner nodules (carcinoma) is seen. The inner flat areas are also recognized (endometriosis).



**Figure 4.** Atypical endometriosis (left) is seen near the inner endometrioid adenocarcinoma cells. HE, x100.

# Relative Risk of Ovarian Cancer in Women with Endometriosis

|                         | Crude            |         | Stratified only  |         | Stratified and adjusted |         |
|-------------------------|------------------|---------|------------------|---------|-------------------------|---------|
|                         | OR (95% CI)      | p value | OR (95% CI)*     | p value | OR (95% CI)†            | p value |
| <u>Invasive</u>         | 1.49 (1.34–1.65) | <0.0001 | 1.53 (1.37–1.70) | <0.0001 | 1.46 (1.31–1.63)        | <0.0001 |
| <u>Clear-cell</u>       | 3.73 (3.04–4.58) | <0.0001 | 3.44 (2.78–4.27) | <0.0001 | 3.05 (2.43–3.84)        | <0.0001 |
| <u>Endometrioid</u>     | 2.32 (1.94–2.78) | <0.0001 | 2.20 (1.82–2.66) | <0.0001 | 2.04 (1.67–2.48)        | <0.0001 |
| Mucinous                | 1.09 (0.76–1.58) | 0.63    | 1.04 (0.71–1.51) | 0.86    | 1.02 (0.69–1.50)        | 0.93    |
| High-grade serous       | 1.11 (0.96–1.29) | 0.16    | 1.16 (1.00–1.35) | 0.056   | 1.13 (0.97–1.32)        | 0.13    |
| <u>Low-grade serous</u> | 2.02 (1.38–2.97) | <0.0001 | 2.22 (1.48–3.31) | <0.0001 | 2.11 (1.39–3.20)        | <0.0001 |
| Borderline              | 1.26 (1.05–1.50) | 0.012   | 1.19 (0.99–1.43) | 0.062   | 1.12 (0.93–1.35)        | 0.24    |
| Mucinous                | 1.27 (0.97–1.67) | 0.078   | 1.19 (0.90–1.57) | 0.23    | 1.12 (0.84–1.48)        | 0.45    |
| Serous                  | 1.31 (1.05–1.63) | 0.015   | 1.28 (1.02–1.61) | 0.034   | 1.20 (0.95–1.52)        | 0.12    |

OR=odds ratio. \*Stratified by age (5 year categories), ethnic origin (non-Hispanic white, Hispanic white, black, Asian, and other). †Stratified by age (5 year categories), ethnic origin (non-Hispanic white, Hispanic white, black, Asian, and other), and adjusted for duration of oral contraceptive use (never, <2 years, 2–4.99 years, 5–9.99 years, ≥10 years), and parity (0, 1, 2, 3, ≥4 children).

**Table 3: Association between history of endometriosis and the histological subtypes of ovarian cancer**

# Summary

- ◆ “There is a recognized association between endometriosis and clear cell, low-grade serous and endometrioid ovarian cancer, but the overall risk of ovarian cancer amongst women with endometriosis remains low, with a relative risk ranging from 1.3 to 1.9, which means that at worst the **life-time risk of ovarian cancer is increased from ~1 in 100 to 2 in 100.**”

Johnson & Hummelshoj, for the WES Montpellier Consortium, *Hum Reprod* 2013

Pearce CL *et al*, *Lancet Oncol* 2012;13:385–394

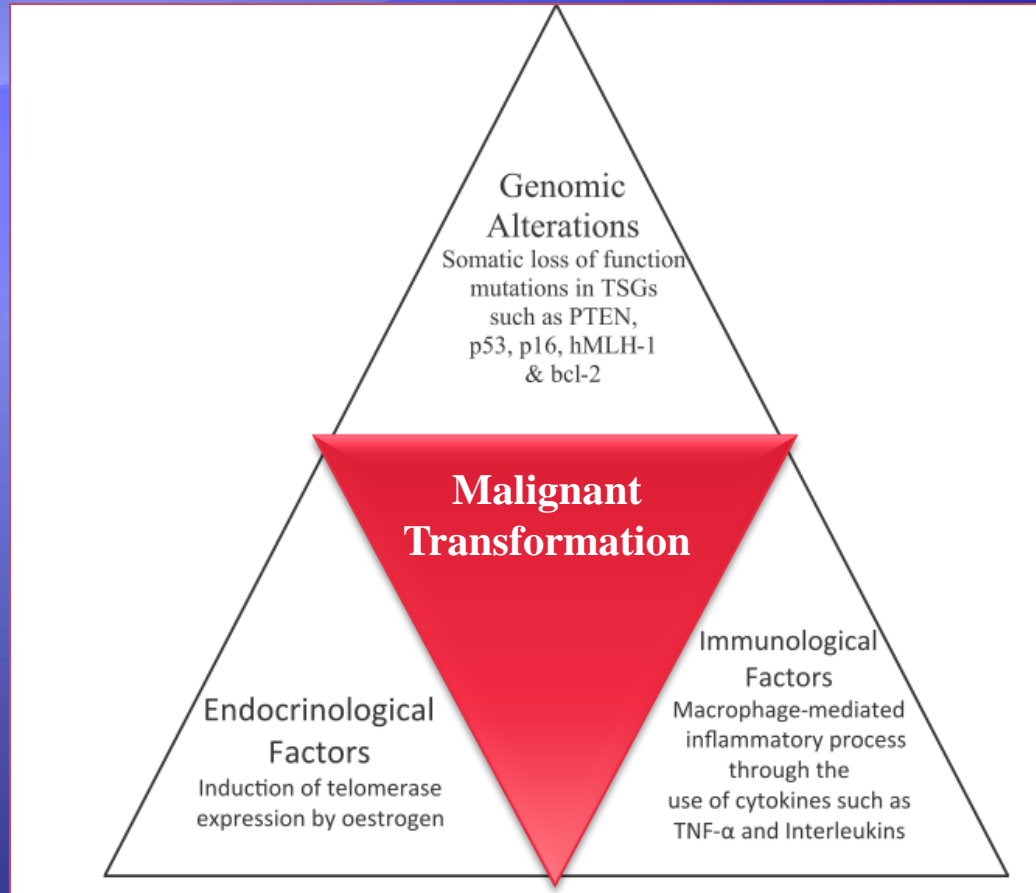
Sayasneh A *et al.*, *Obstet Gynecol* 2011;2011:1403–1410.

Kim HS, Kim TH, Chung HH, Song YS. Risk and prognosis of ovarian cancer in women with endometriosis: a meta-analysis. *Br J Cancer*. 2014 Feb 11

# Objectives

- ◆ Overview of endometriosis and ovarian cancer
- ◆ Pathogenesis of malignant transformation of endometriosis
- ◆ Clinical applications
- ◆ Future investigation

# Features shared by endometriosis and cancer



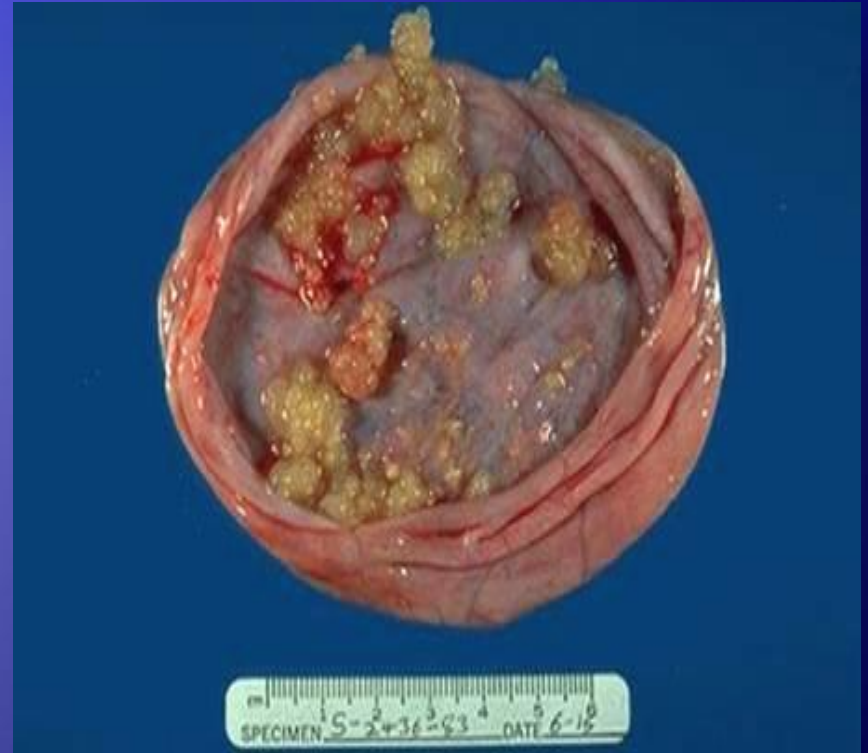Pollaco et al. *Gynecological Endocrinology*, 2012

DOI: 10.3109/09513590.2011.650761

# Clinical Applications

# Clinical Applications

- ◆ **Ovarian cancer**
  - ◆ 2<sup>nd</sup> most common gynecologic malignancy in developed countries
- ◆ **in the U.S.**
  - ◆ 22,000 new cases
  - ◆ 14,000 cancer-related deaths expected from ovarian cancer in 2013
- ◆ **lifetime risk is 1:70 and the average age at diagnosis of ovarian cancer in the US is 63 years old**



*Siegel R et al. Cancer statistics, 2013. CA Cancer J Clin. 2013 63(1):11-30.*



# Ovarian Cancer

- ◆ 30% diagnosed at Stage I-II. Better prognosis
- ◆ However 50% ovarian cancers diagnosed early stage need another surgery (unexpected diagnosis) and most are **Endometrioid and Clear cell carcinoma**
- ◆ >60% diagnosed in advanced stages (majority are **High Grade Serous**). Poor prognosis

# STAGE I OVARIAN CARCINOMA: DIFFERENT CLINICAL PATHOLOGIC PATTERNS

76 PATIENTS WITH STAGE I OVARIAN  
CARCINOMA UNDERWENT SURGICAL STAGING  
AND CYTOREDUCTION

*Deligdisch L, Penault-Llorca F, Schlosshauer P, Altchek A, Peiretti M, Nezhat F  
Fertil Steril 2007;88(4):906-10*

| Clinical Features         | Ovarian Serous Papillary CA (n=22) | Ovarian Endometrioid CA (n=40) | Ovarian Clear Cell CA (n=10) | Mixed endometrioid / clear cell CA (n=4) |
|---------------------------|------------------------------------|--------------------------------|------------------------------|--|
| Average age               | 61.05                              | 52.9                           | 58.6                         | 52.2                                     |
| Asymptomatic pelvic mass  | <b>13</b>                          | 3                              | --                           | --                                       |
| Symptomatic pelvic mass   | 2                                  | <b>19</b>                      | <b>10</b>                    | 4  |
| Abnormal Vaginal bleeding | 1                                  | <b>19</b>                      | <b>1</b>                     | 99                                       |
| H/o breast CA             | 8                                  | --                             | 1                            | --                                       |
| BRCA mutations, tested    | 4                                  | --                             | --                           | --                                       |
| Ascites                   | 2                                  | --                             | 1                            | --                                       |

| Pathology                         | Serous Papillary<br>n (%) | Endometrioid<br>n (%) | Clear cell<br>n (%) | Mixed endometrioid and clear cell<br>n (%) | Total<br>n (%) | P value   | RR    |
|-----------------------------------|---------------------------|-----------------------|---------------------|--|----------------|-----------|-------|
| <b>Total</b>                      | 22 (30)                   | 40 (53)               | 10 (13)             | 4 (5)                                      | 76 (100)       |           |       |
| <b>Bilateral ovarian tumors</b>   | 11 (14)                   | 3 (4)                 | 1 (1.3)             | 1 (1.3)                                    | 16 (21)        | 0.00027   | 0.27  |
| <b>Ovarian endometriotic cyst</b> | 1 (1.3)                   | <b>29 (38)</b>        | <b>7 (9)</b>        | <b>3 (4)</b>                               | 40 (53)        | 0.0000001 | 23.33 |
| <b>Pelvic endometriosis</b>       | 1 (1.3)                   | <b>14 (18)</b>        | <b>1 (1.3)</b>      | <b>1 (1.3)</b>                             | 17 (22)        | 0.038     | 6.05  |

| Pathology                       | Serous Papillary<br>n (%) | Endometrioid<br>n (%) | Clear cell<br>n (%) | Mixed<br>endometrioid<br>and clear cell<br>n (%) | Total<br>n (%) | P value | RR  |
|---------------------------------|---------------------------|-----------------------|---------------------|--|----------------|---------|-----|
| Endometrial carcinoma           | 1 (1.3)                   | <b>17 (22)</b>        | <b>1 (1.3)</b>      | --   | 19 (25)        | 0.0086  | 7.0 |
| Endometrial polyp / Hyperplasia | 3 (4)                     | <b>11 (14)</b>        | <b>2 (3)</b>        | <b>2 (3)</b>                                     | 16 (21)        | NS      |     |
| <b>TOTAL</b>                    | 4 (5.3)                   | <b>28(36)</b>         | <b>3(4.3)</b>       | <b>2(3)</b>                                      | 16 (21)        |         |     |

# Results

- Nonserous ovarian carcinomas comprised over 2/3 of the stage I ovarian carcinomas
- Most patients with serous carcinoma presented with asymptomatic pelvic masses
- Nonserous carcinomas presented with pelvic pain, abnormal vaginal bleeding, with or without a pelvic mass
- Endometrial abnormalities 36%
- (Hyperplasia and carcinoma)

# Pathophysiology of Epithelial Ovarian Cancer-

## Two different pathways producing two distinct subsets?

- ◆ Recent studies suggest EOC can be divided into two groups based on shared genetic mutations and observed progression from a precursor lesion

- ◆ Type 1

Low-grade serous, endometrioid, and clear cell carcinomas present at an earlier stage. These are more indolent, are associated with PTEN , BCL2 and/or ARID1A mutation, and likely arise from **endometriosis**

- ◆ Type 2:

- ◆ High grade serous CA, usually present in advanced stage
- ◆ Commonly show p53 mutations
- ◆ Usually **not** associated with adjacent borderline serous tumors, and likely arise from **tubal epithelium**

*. Pearce CL et al, on behalf of the Ovarian Cancer Association Consortium. Association between endometriosis and risk of histological subtypes of ovarian cancer: a pooled analysis of case-control studies. Lancet Oncol 2012;13:385-394*

Folkens AK, Jarobe EA, Roh MH, Crum CP. Precursors to pelvic serous carcinoma and their clinical implications. Gyn Onc. 2009. 113: 391-396

# What Screening , Diagnostic and Preventive Opportunities are Available to Practitioners for Women with Endometriosis?

- ◆ Screening for genetic mutations in ovarian cancer is just the beginning, and an emerging concept of a dual model of ovarian carcinogenesis divides ovarian carcinomas into two groups
- ◆ High-grade serous carcinomas tend to present at an advanced stage, are associated with TP53 mutations, and likely arise from tubal epithelium
- ◆ Low-grade serous, endometrioid, and clear cell carcinomas present at an earlier stage. These are more indolent, are associated with PTEN , BCL2 and/or ARID1A mutation, and likely arise from endometriosis
- ◆ Currently however, there is not sufficient data to recommend mutation screening tests in patients with endometriosis

*Pearce CL et al, on behalf of the Ovarian Cancer Association Consortium. Association between endometriosis and risk of histological subtypes of ovarian cancer: a pooled analysis of case-control studies. Lancet Oncol 2012;13:385-394.*  
*Folkins AK et al. Precursors to pelvic serous carcinoma and their clinical implications. Gyn Onc. 2009. 113:391-396.*

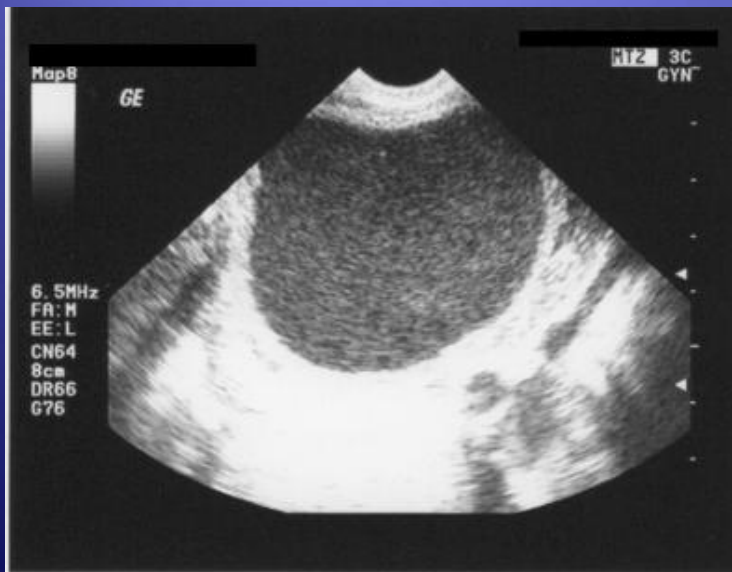

# What Screening , diagnostic and Preventive Opportunities are Available to Practitioners for Women with Endometriosis?

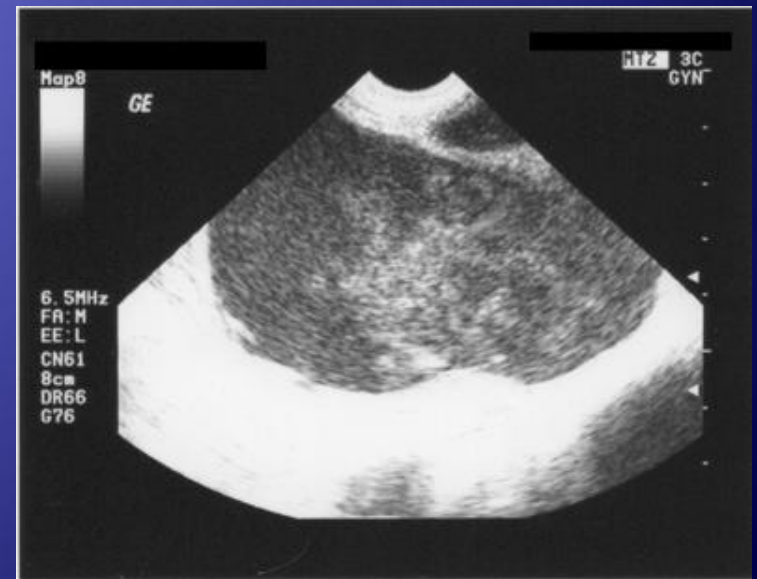## Pelvic U/S

- ♦ useful in the identification of ovarian endometrioma with homogeneous hypoechoogenic cystic features and those with mural malignant changes
- ♦ difficult to detect relatively small endocystic echogenic components with this modality

Endometrioma with diffuse, homogenous hypoechoogenic features



Endometrioma with mural malignant features



# What Screening and Diagnostic Opportunities are Available to Practitioners for Women with Endometriosis?

## ◆ MRI

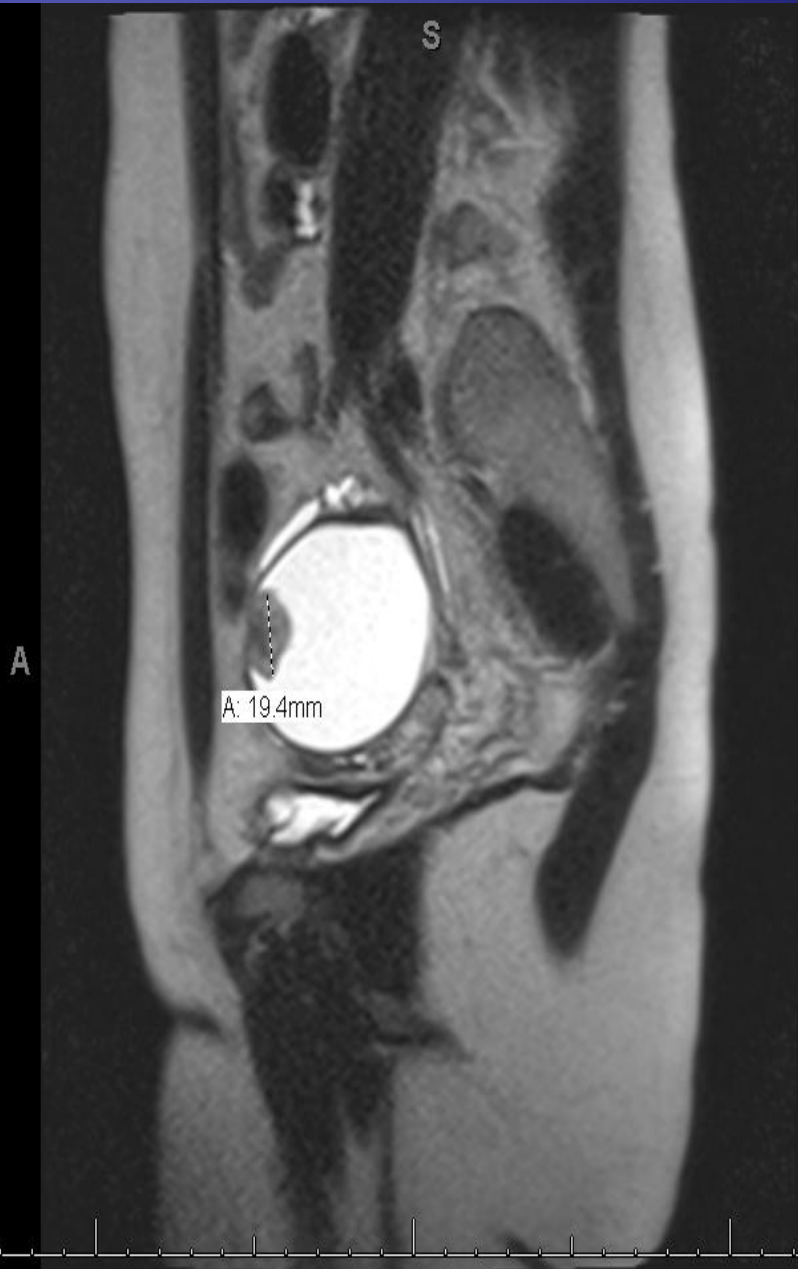
- ◆ more useful to both visualize endometriomas and possibly detect malignant transformation
- ◆ hyperdense mural nodules within the ovary and rapid growth of an endometrioma can be visualized on MRI – associated with malignant transformation
- ◆ In a cohort study comparing MRI findings of 10 patients with ovarian adenocarcinoma to 10 patients with benign endometriomas, Tanaka and colleagues found mural nodules in all 10 malignancies but in only 3 of the benign cases

*Tanaka YO et al. Ovarian carcinoma in patients with endometriosis: MR imaging findings. Genitourinary Imaging 2000; 125*

*Takeuchi M et al. Malignant transformation of pelvic endometriosis: MR imaging findings and pathologic correlation. Radiographics. March 2006;26:407-417*

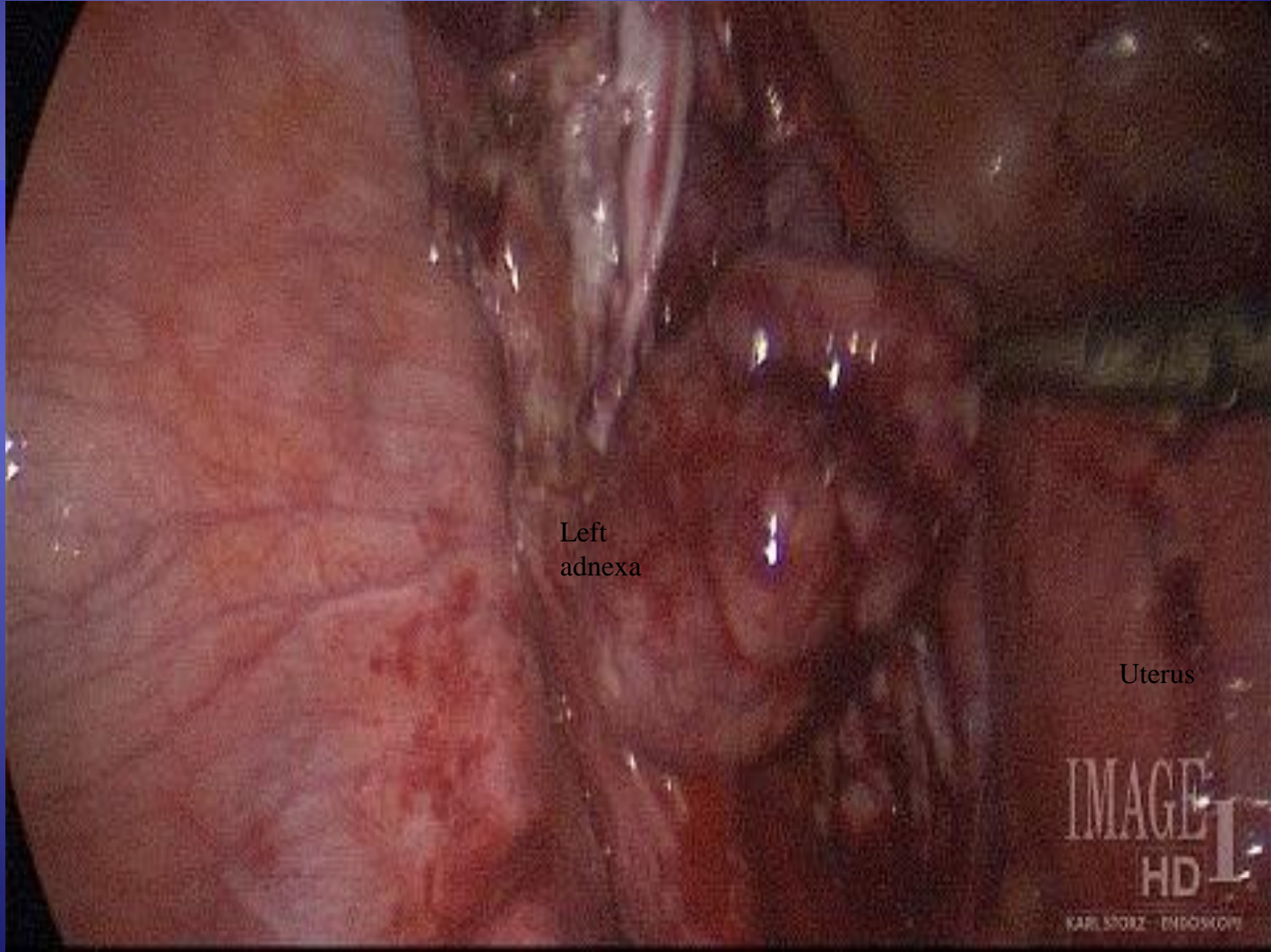
MITWALLY, DALIA, M  
M1187297  
Age: 038Y F  
Series # 4  
Image # 9/30  
4.00 mm

Valley Hospital  
Pelvis\*OBGYN  
12/4/2013



256  
TRTR 1100  
TETE 116  
www.lwi 981.366  
Key

Key Image  
Zoom: 139.8%



Left  
adnexa

Uterus

IMAGE  
HD  
KARL STORZ - ENDOSKOPIE

# **What Preventative Measures can be Offered to Women with Endometriosis?**

# Endometriomas Classifications

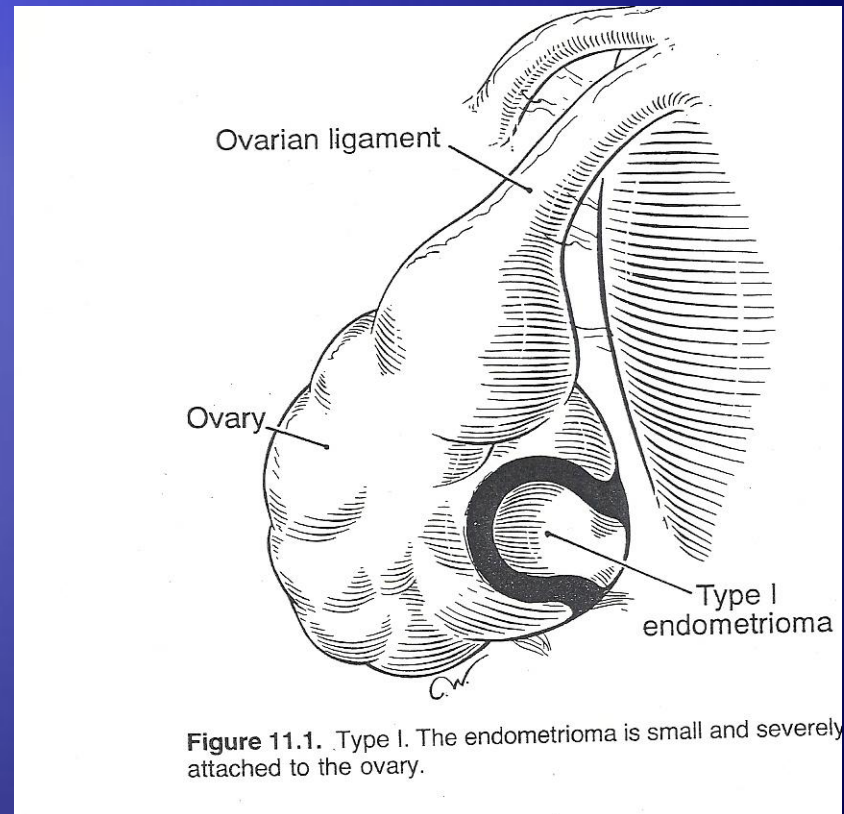
- ◆ **A Clinical and histologic classification of endometriomas**
- ◆ **Nezhat F et al. J reprod Med 1992;37:771**

# Nezhat Classification

## Type 1

### Primary endometrioma

- ◆ Same origin as peritoneal endometriosis
- ◆ Difficult to remove due to fibrosis
- ◆ Removed in pieces



# Nezhat Classification

Type II:

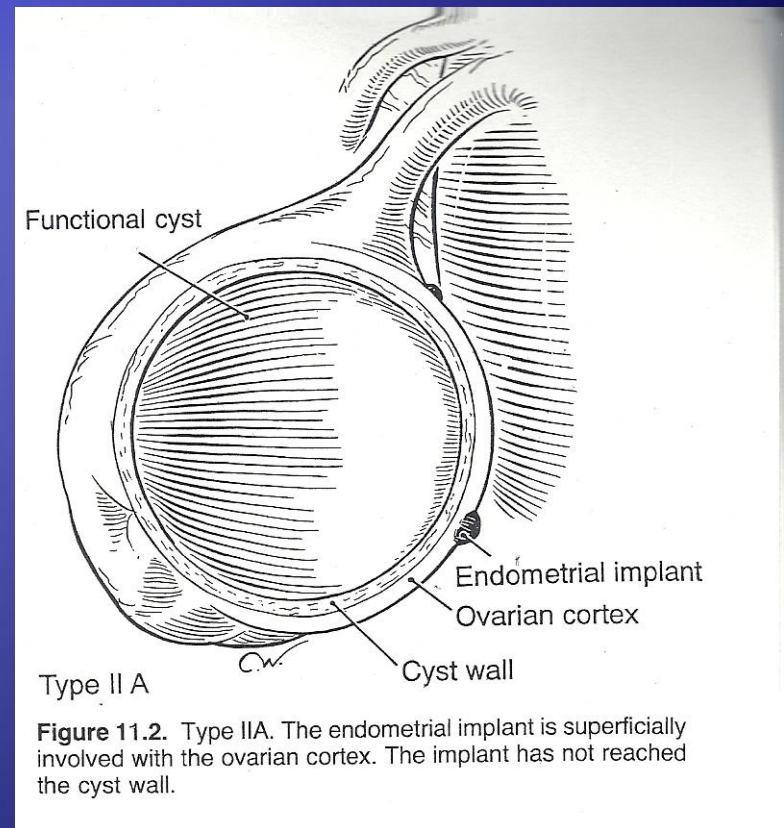
Secondary endometrioma

- ◆ **Follicular or luteal cyst invaded by cortical endometriosis**



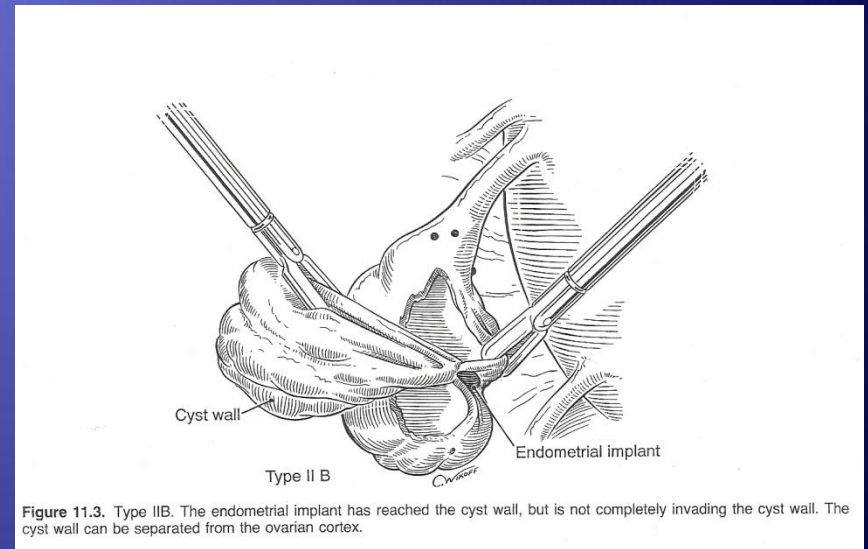
# Nezhat Classification

- IIA: superficial endometriosis implants without penetration of cyst, thus cyst easily separable from cortex



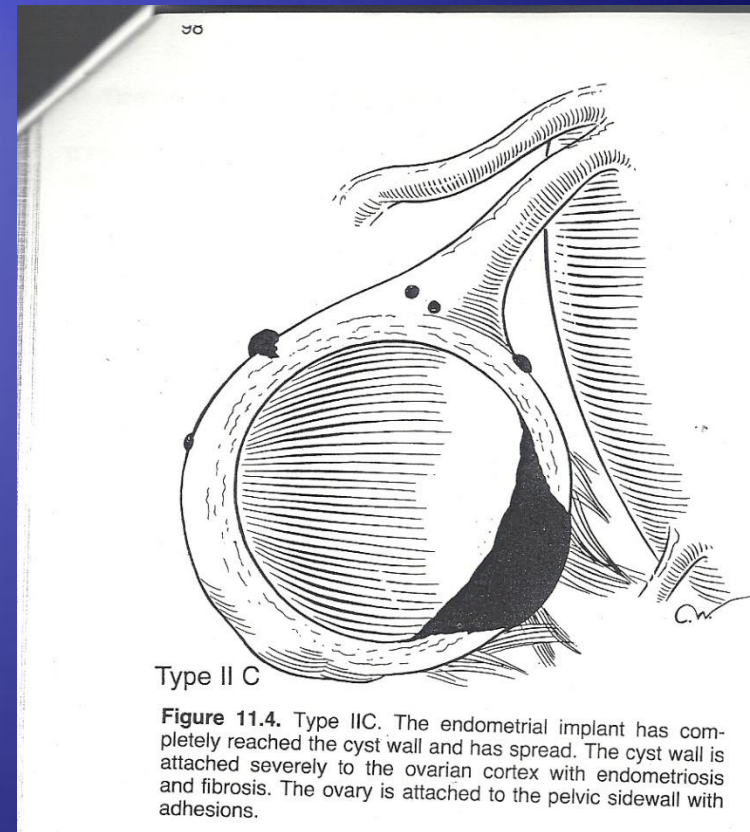
# Nezhat Classification

- IIB: endometriosis area deeper, cyst wall adherent to cortex



# Nezhat Classification

- IIC: endometriosis is deep invading cyst and cyst wall, difficult separation between cortex and cyst



# What Preventative Measures can be Offered to Endometrioma?

- ◆ Most endometriomas are composed of endometrial implants, which invade a functional cyst
- ◆ Hormonal therapy
  - ◆ hormonal therapy alone however often fails to cause total regression of endometriomas, and is most effective following thorough surgical excision of endometriomas and associated endometriosis.
  - ◆ a review of the literature by Vercellini and colleagues comparing diligent post-operative oral contraceptive versus sporadic use demonstrated a pooled odds ratio of 0.21 (95% CI 0.11-0.40) for ovarian endometrioma recurrence
  - ◆ Koga et al presented similar findings, with GnRH agonists, OCPs, levonorgestrel IUD, and pregnancy

*Vercellini P, De Matteis S, Somigliana E, et al. Long-term adjuvant therapy for the prevention of postoperative endometrioma recurrence: a systematic review and meta-analysis. Acta Obstetrica et Gynecologica 2012;92(1):8-16.*

*Nezhat F, Nezhat C, Allan CJ, et al. A clinical and histological classification of endometrioma: Implications for a mechanism of pathogenesis. J Reprod Med 1992;37:771*

*Nezhat C, Nezhat FR, Nezhat CH, Admon D. Treatment of Ovarian Endometriosis. In: Nezhat CR, editor. ed. Endometriosis: Advanced Management and Surgical Techniques. Springer-Verlag; 1995.*

*Koga K, Osuga Y, Takemura Y, et al. Recurrence of endometrioma after laparoscopic excision and its prevention by medical management. Front Biosci 2013;5:676-83.*

# What Preventative Measures can be Offered to Endometrioma?

- ◆ Most endometriomas are composed of endometrial implants, which invade a functional cyst
- ◆ Hormonal therapy
  - ◆ hormonal therapy alone however often fails to cause total regression of endometriomas, and is most effective following thorough surgical excision of endometriomas and associated endometriosis.
  - ◆ a review of the literature by Vercellini and colleagues comparing diligent post-operative oral contraceptive versus sporadic use demonstrated a pooled odds ratio of 0.21 (95% CI 0.11-0.40) for ovarian endometrioma recurrence
  - ◆ Koga et al presented similar findings, with GnRH agonists, OCPs, levonorgestrel IUD, and pregnancy

*Vercellini P, De Matteis S, Somigliana E, et al. Long-term adjuvant therapy for the prevention of postoperative endometrioma recurrence: a systematic review and meta-analysis. Acta Obstetrica et Gynecologica 2012;92(1):8-16.*

*Nezhat F, Nezhat C, Allan CJ, et al. A clinical and histological classification of endometrioma: Implications for a mechanism of pathogenesis. J Reprod Med 1992;37:771*

*Nezhat C, Nezhat FR, Nezhat CH, Admon D. Treatment of Ovarian Endometriosis. In: Nezhat CR, editor. ed. Endometriosis: Advanced Management and Surgical Techniques. Springer-Verlag; 1995.*

*Koga K, Osuga Y, Takemura Y, et al. Recurrence of endometrioma after laparoscopic excision and its prevention by medical management. Front Biosci 2013;5:676-83.*

# What Preventative Measures can be Offered to Endometrioma?

- ◆ Most endometriomas are composed of endometrial implants, which invade a functional cyst
- ◆ Hormonal therapy
  - ◆ hormonal therapy alone however often fails to cause total regression of endometriomas, and is most effective following thorough surgical excision of endometriomas and associated endometriosis.
  - ◆ a review of the literature by Vercellini and colleagues comparing diligent post-operative oral contraceptive versus sporadic use demonstrated a pooled odds ratio of 0.21 (95% CI 0.11-0.40) for ovarian endometrioma recurrence
  - ◆ Koga et al presented similar findings, with GnRH agonists, OCPs, levonorgestrel IUD, and pregnancy

*Vercellini P, De Matteis S, Somigliana E, et al. Long-term adjuvant therapy for the prevention of postoperative endometrioma recurrence: a systematic review and meta-analysis. Acta Obstetrica et Gynecologica 2012;92(1):8-16.*

*Nezhat F, Nezhat C, Allan CJ, et al. A clinical and histological classification of endometrioma: Implications for a mechanism of pathogenesis. J Reprod Med 1992;37:771*

*Nezhat C, Nezhat FR, Nezhat CH, Admon D. Treatment of Ovarian Endometriosis. In: Nezhat CR, editor. ed. Endometriosis: Advanced Management and Surgical Techniques. Springer-Verlag; 1995.*

*Koga K, Osuga Y, Takemura Y, et al. Recurrence of endometrioma after laparoscopic excision and its prevention by medical management. Front Biosci 2013;5:676-83.*

# **What Preventative Measures can be Offered to Women with Endometriosis?**

**When endometriosis is diagnosed, surgical resection remains the most effective treatment**

# Ovarian cancer Association Consortium (OCAC)

## ◆ Tubal ligation

- ◆ 38% ↓ Endometrioid carcinoma
- ◆ 52% ↓ Clear cell carcinoma
- ◆ 19% ↓ High-grade serous carcinoma



# SGO Clinical Practice Statement: Salpingectomy for Ovarian Cancer Prevention

*“ For women at population risk (average) for ovarian cancer, salpingectomy should be considered (after completion of childbearing) at the time of hysterectomy, in lieu of tubal ligation, and also at the time of other pelvic surgery “*

# Hormonal and surgical treatments for endometriosis and risk of epithelial ovarian cancer

ANNA-SOFIA MELIN<sup>1,2</sup>, CECILIA LUNDHOLM<sup>1</sup>, NINOA MALKI<sup>1</sup>, MARJA-LIISA SWAHN<sup>2</sup>, PÄR SPARÈN<sup>1</sup> & AGNETA BERGQVIST<sup>1,3</sup>

<sup>1</sup>Department of Medical Epidemiology and Biostatistics, Karolinska Institute, Stockholm, <sup>2</sup>Department of Obstetrics and Gynecology, Karolinska University Hospital, Huddinge, and <sup>3</sup>Department of Clinical Science and Education, Södersjukhuset, Karolinska Institute, Stockholm, Sweden

- ◆ **220 cases and 416 controls entered the study**
- ◆ **Information on hormonal and surgical treatments, and other reproductive factors was extracted from medical records according to pre-specified protocols**

# Hormonal and surgical treatments for endometriosis and risk of epithelial ovarian cancer

ANNA-SOFIA MELIN<sup>1,2</sup>, CECILIA LUNDHOLM<sup>1</sup>, NINOA MALKI<sup>1</sup>, MARJA-LIISA SWAHN<sup>2</sup>, PÄR SPARÈN<sup>1</sup>  
& AGNETA BERGQVIST<sup>1,3</sup>

<sup>1</sup>Department of Medical Epidemiology and Biostatistics, Karolinska Institute, Stockholm, <sup>2</sup>Department of Obstetrics and Gynecology, Karolinska University Hospital, Huddinge, and <sup>3</sup>Department of Clinical Science and Education, Södersjukhuset, Karolinska Institute, Stockholm, Sweden

- ◆ **Strong reduction in risk of epithelial ovarian CA:**
  - ◆ One-sided oophorectomy , multivarian analysis (OR 0.19, 95%CI 0.28-0.62)
  - ◆ Complete extirpation of endometriotic tissue (OR 0.30, 95%CI 0.25-0.55)

# Summary

- ◆ **There is now an unprecedented opportunity to develop a comprehensive plan for screening women with endometriosis for early detection and prevention of specific types of ovarian cancer**

# Ovarian Cancer

- ◆ **Lifetime risk (general population):** **1.4 %**
- ◆ **BRCA 1 mutation carrier:** **60 %**
- ◆ **BRCA 2 mutation carrier:** **30%**
- ◆ **HNPCC** **10%**
- ◆ **Endometriosis** **2-3%**

Prat J, Ribe A, Gallardo A. Hereditary ovarian cancer. Hum Pathol. 2005; 36:861-870

Karlan B, et al. Discussion: hereditary ovarian cancer. Gynecologic Oncology. 2003;88:S11-S3

King MC, Marks JH, Mandell JB. Breast and ovarian cancer risks due to inherited mutations in BRCA1 and BRCA2. Science. 2003;88:S11-S3

Boyd J. Specific keynote: hereditary ovarian cancer: what we know. Gynecol Oncol. 2003;88(1 Pt 2):S8-S10;discussion S11-S13

# **Delineating Which Patients May be at an Increased Risk for Ovarian Cancer**

- ◆ **Both, the gynecologist and the general practitioner should pay special attention to patients with endometriosis and the following history:**
  - ◆ Long-standing endometriosis
  - ◆ Endometriosis diagnosed at an early age
  - ◆ Endometriosis associated with infertility and/or history of infertility treatment
  - ◆ Patients with ovarian endometriomas

# How should we approach treatment options for women with endometriosis who are determined to be at an increased risk for ovarian cancer?

- ◆ Identification of all women with endometriosis, either surgically documented or self-reported by symptoms
- ◆ Hormonal treatment aimed at reducing the risk of recurrent endometriosis and endometriomas
- ◆ Careful follow up of ovarian endometriomas with imaging studies, particularly MRI when Us is suspicious, to detect any characteristic changes such as mural formation
- ◆ Fertility preservation; embro, egg and tissue freezing should be considered.

# How should we approach treatment options for women with endometriosis who are determined to be at an increased risk for ovarian cancer?

- ◆ **Treatment planning:**
  - ◆ Complete surgical resection of all endometriotic foci in women undergoing surgical treatment, with tissue evaluation of ovarian endometriomas to rule out malignancy
  - ◆ Oophorectomy and salpingectomy Should be individualized Base on the patients Risk and desires



# Future Studies

- ◆ **Further research is needed to understand the genomic and immunologic pathways of endometriosis**
  - It may be accomplished by larger studies with direct evaluation of endometriosis tissue

**6<sup>th</sup>** annual seminar on

# Minimally Invasive Gynecologic Surgery

*with hands-on workshop on laparoscopic suturing and knot-tying*

**Save the Date**

DECEMBER

**11 12**

**BEST Comprehensive Overview on  
Prevention and Management of  
Complications**

## HIGHLIGHTS

- Laparoscopic & Robotic Hysterectomy: Step-by-Step
- Enhance Performance and Achieve Proficiency in Suturing and Knot-Tying Techniques
- Improve Surgical Efficiency, Patient Outcomes and Satisfaction, Decrease Risks of Complications, and Cut Costs
- Safe n' Simple: Create Bladder Flap, Remove Cervix, Repair Bladder, Bowel & Ureter Injury
- Advances in Gynecologic Surgery: Technology and Instruments in Robotic Surgery
- Open Forum Discussions with Experts: Tips & Tricks, Pearls & Pitfalls of Suturing
- Live Surgery Telecasts and Video Sessions
- da Vinci Robot Test Drive & Mimic Simulation Training

**General Chair:**

**Scientific Program Co-Chairs:**

Farr R. Nezhat, MD

Camran Nezhat, MD

Ceana Nezhat, MD

The Roosevelt Hotel New York, New York

**For more information, please visit:**

<http://nezhat.org/camran/6th-Annual-seminar-on-Minimally-Invasive-Gynecologic-Surgery.php>



Thank you