

BENEFITS OF FETAL ULTRASOUND FOR THE DIAGNOSIS OF INTERVENTRICULAR SEPTAL DEFECT

Ben Miled S, Belghith C, Kehila M, Ben Miled C, Chelli D

Maternity & Neonatology Center of Tunis

INTRODUCTION


- Congenital heart defect (CHD) is a significant cause of neonatal and infant mortality.
- The interventricular communication is the most common CHD.
- Prenatal diagnosis of structural or functional abnormalities can be useful not only for appropriate patient counselling about expected prognosis but also for outlining the management plan to improve the care and support provided to the foetus, mother and family.

OBJECTIVES

- Determine the sensitivity and specificity of ultrasonography in the diagnosis of interventricular communication, through anatomical-ultrasound confrontation.

MATERIALS AND METHODS

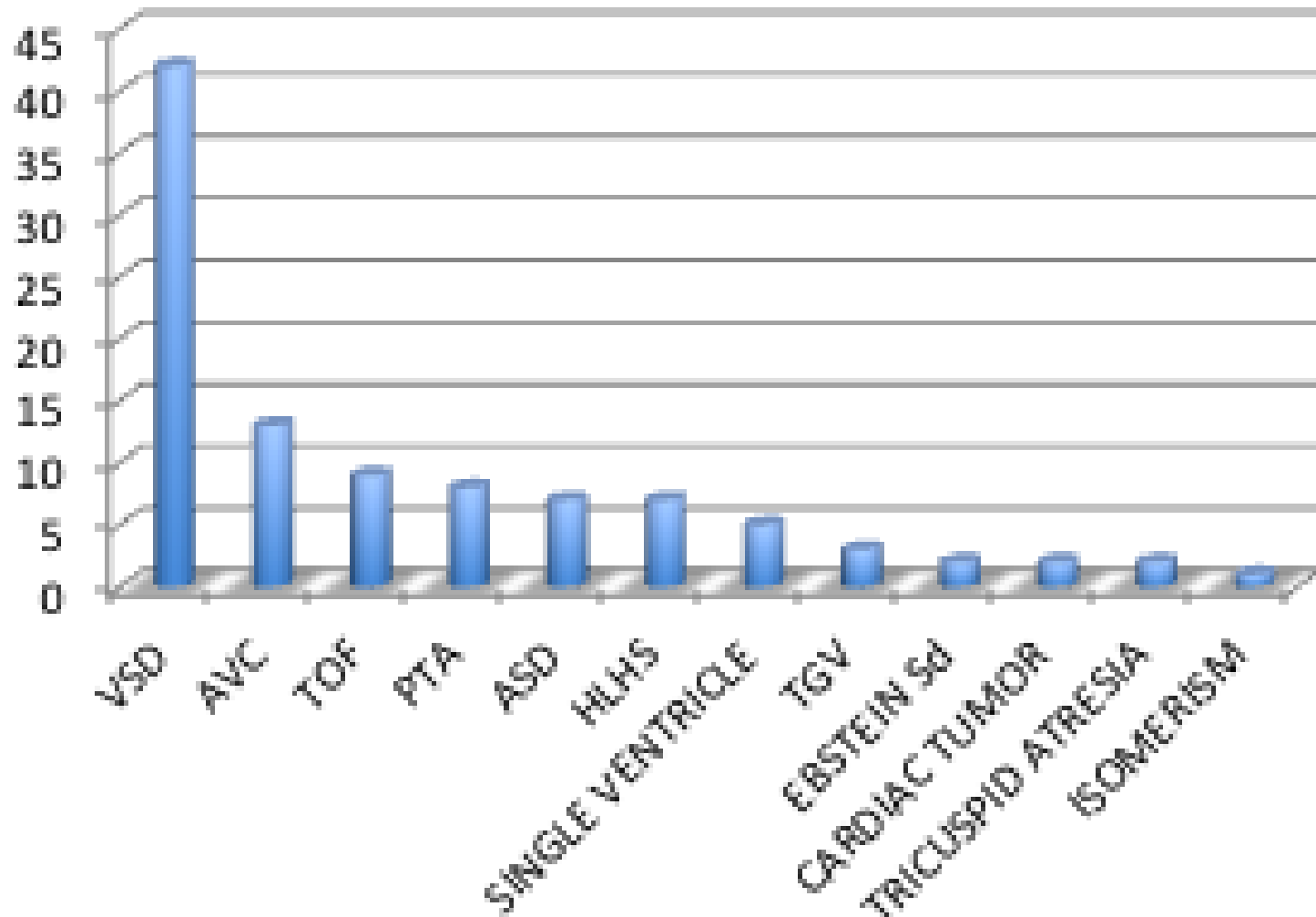
- Retrospective study conducted at the Maternity and Neonatal Center of Tunis in the Embryo - Foetopathology department, referencing all cases of congenital heart diseases, in particular : cases of ventricular septal defect (VSD), over a period of 2 years, from January 2011 to December 2012.

- 
- Imaging typically included evaluation of the four-chamber heart, great arteries and venous return to look for intra- or extra-cardiac malformations.

RESULTS

- Eighty-five cases of **C**ongenital **H**eart **D**isease (**CHD**), which represents a frequency of 5.73 %, were recorded in 1482 foeto-pathologic examinations.
- Out of the 85 detected heart diseases, 42 were **V**entricular **S**eptal **D**efect (**VSD**), which represents a frequency of 49 %.

Graph shows the spectrum of major congenital heart defects (CHD)



VSD - Maternal characteristics

- **AGE** : Average patients's age was 32,66 (19 to 45)

- **GRAVIDITY – PARITY** :
 - ▣ Average gravidity 2,69
 - ▣ Average parity 1,44

- **PERSONAL HISTORY** :
 - ▣ 2 patients had a background of fetal cardiac heart disease
 - ▣ 4 patients had a history of miscarriage
 - ▣ 1 patients had a history of fetal death

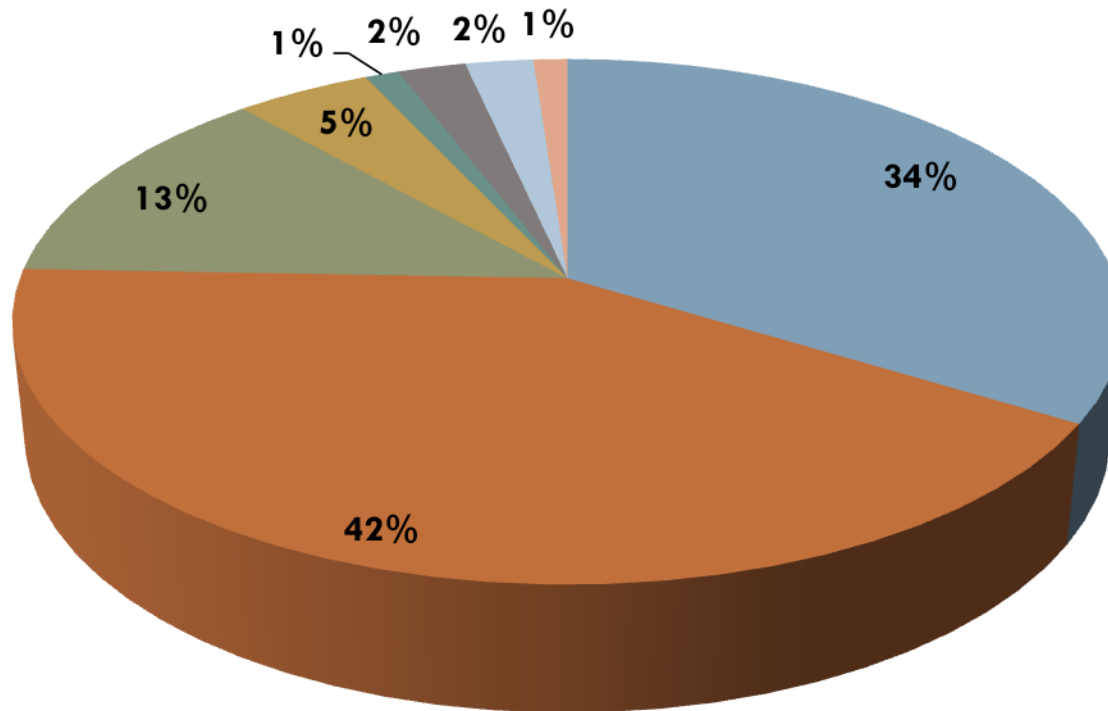
VSD - Maternal characteristics

- **PARENTAL CONSANGUINITY** : found in 16,73%

- **BLOOD GROUP** :
 - ▣ O+ in 42,3%
 - ▣ A+ in 34%

VSD - Maternal characteristics

■ A+ ■ O+ ■ B+ ■ AB+ ■ A- ■ O- ■ B- ■ AB-



VSD - Fetal characteristics

- Of the 42 fetuses with VSD, 22 (52,3%) were female

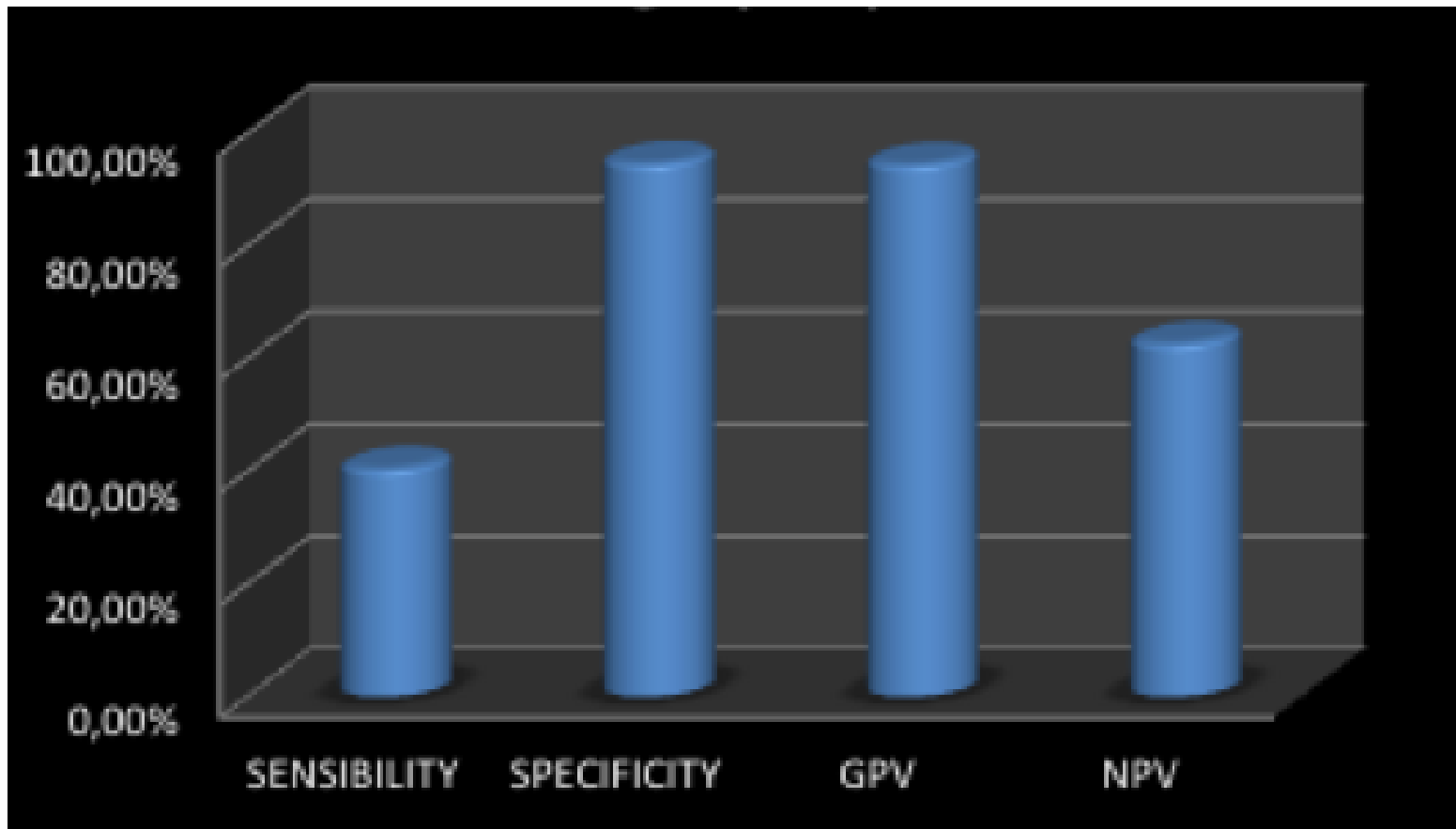
- Only 10 karyotyping was performed :
 - ▣ 2 chromosome abnormalities
 - 1 Down Dyndrom,
 - 1 translocation 46XX t (9,18)(P12,P11)
 - ▣ 8 were normal


Ultrasound in the diagnosis of VSD

	VSD (+)	VSD (-)	Total
Ultrasound (+)	17	1	18
Ultrasound (-)	25	42	67
Total	42	43	85

Ultrasound in the detection of VSD

- Sensitivity was 40.47 %
- Specificity was 97.67 %
- Good positive predictive value of 94.44 %
- Negative predictive value was 62.68 %.



- 
- In our series, the combination of VSD and other heart diseases was found in 43% of cases.

 - It was mainly represented by a
 - ▣ Persistent Truncus Arteriosus (**PTA**) in 4 cases

 - ▣ Atrial septal defect (**ASD**) in 4 cases

VSD associated to other CHD

	Number	Percentage
Atrial septal defect	4	23,5 %
Persistent truncus arteriosus	4	23,5 %
Tetralogie of Fallot	2	12 %
Hypoplastic left heart syndrome	2	12 %
Transposition of the great vessels	2	12 %
Tricuspid atresia	2	12 %
Dextrocardia	1	5 %

VSD and Extra-cardiac malformations

- The extracardiac malformations associated with VSD were noticed in 83% of cases

- Mainly :
 - ▣ craniofacial anomalies in 43 % of cases
 - ▣ anomalies of the extremities in 36 % of cases

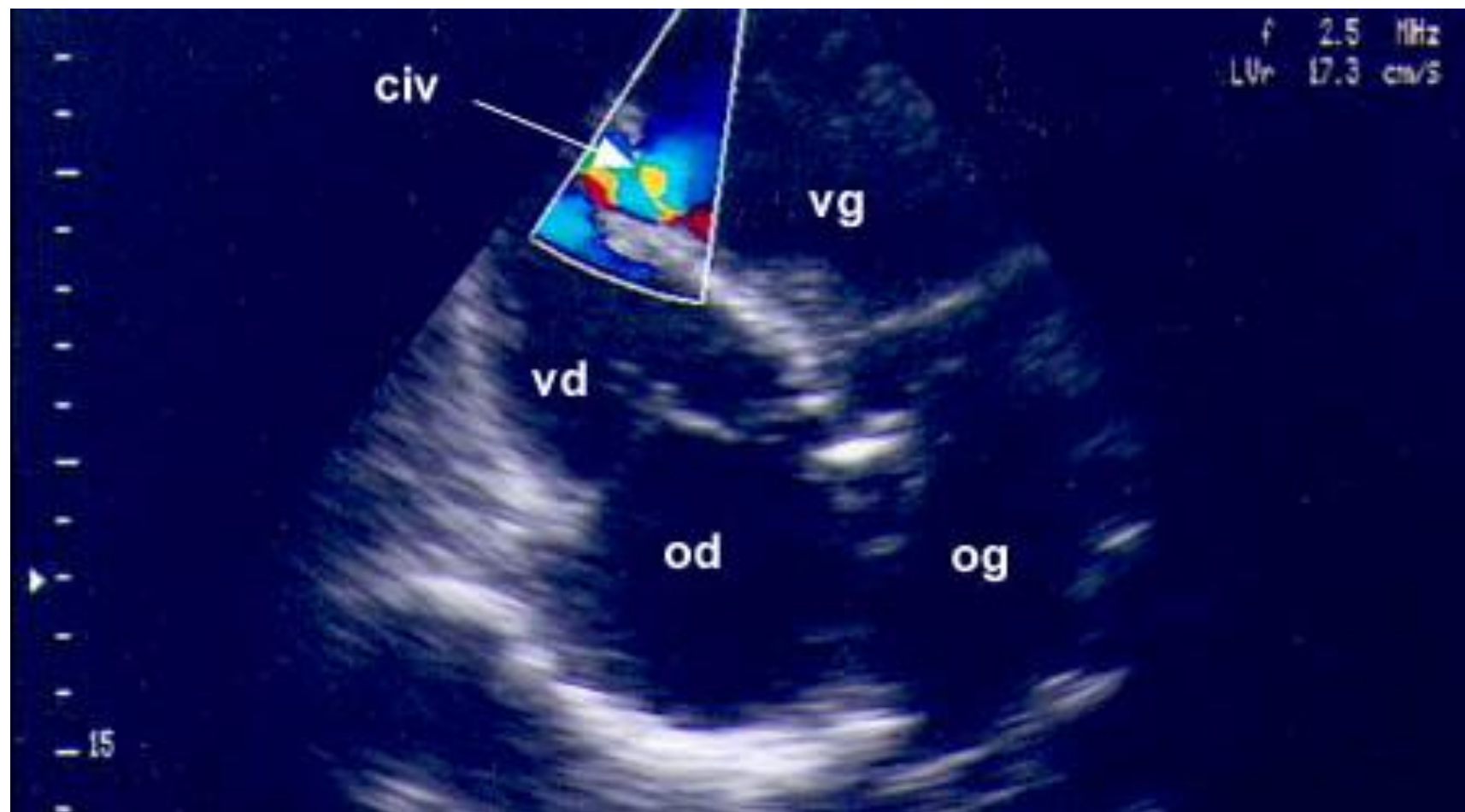
Extra-cardiac malformations associated to VSD

	Number	Percentage
Craniofacial abnormalities	18	43 %
Extremity's abnormalities	15	36 %
Bilateral renal agenesis	5	12 %
Omphalocele	5	12 %
Abnormal lung lobulation	4	10 %
Hydrocephalus	4	10 %
Left diaphragmatic hernia	3	7 %
Imperforate anus	3	7 %
Common mesentery	3	7 %
Anasarca / Ascites	2	5 %
Rachischisis	1	3 %
Tracheo-oesophageal fistula	1	3 %
Gastroschisis	1	3 %

DISCUSSION


- Ventricular septal defects mainly occur in membranous and muscular intervals or at their border.
- The most common ventricular septal defects in the neonatal period occur in the region of the muscular septum [2] .

- Women at high risk of foetal abnormality due to thickened nuchal translucency at FTS and/or maternal medical or past obstetric histories should be referred for early cardiac imaging at 15 weeks [4] .
- For other patients, cardiac imaging can be arranged for the first time at 18–20 weeks of gestation [1-4] .



- The five heart transverse planes according to Yagel et al.'s description allows diagnosis of congenital heart disease (CHD).
- The sensitivity of detecting VSD with single four-chamber view is about 60%
- The sensitivity increased if other transverse planes were combined [2]

- Sometimes, cases with small VSD are missed prenatally, probably because the ovale foramen and ductus arteriosus are open prenatally, which cause the same pressure in the right ventricle and the left ventricle, therefore there is no shunt through the VSD prenatally and the small defect is beyond the ultrasound resolving power [1]

- 
- VSD is known to be associated with chromosomal aberrations and extracardiac anomalies [4]
 - The prognosis is favourable. Most of the patients experience spontaneous closure and show a very low mortality rate which is basically related to extracardiac anomalies [2].

CONCLUSION

- The ventricular septal defect is a common congenital heart disease.
- The antenatal diagnosis can lead to look for other associated abnormalities or chromosomal aberrations and allows us to determine a therapeutic strategy.

REFERENCES

- [1] Prenatal diagnosis of congenital fetal heart abnormalities and clinical analysis, Hui Li et al. Univ Sci B. 2005 September; 6(9): 903–906
- [2] Beramendi Calero et al. ; Interventricular n in the neonatal period, An Esp Pediatr. 1998 Sep; 49 (3):284-8.
- [3] Stoll C, Dott B, Alembik Y, De Geeter B. Evaluation and evolution during time of prenatal diagnosis of congenital heart diseases by routine fetal ultrasonographic examination. Ann Genet 2002; 45:21-7
- [4] Incidence and outcome of prenatally diagnosed, chromosomally normal congenital heart defect in Singapour, Tuntas Dharnadhono et al, Singapore Med J 2012; 53(10) : 643