

**Normal Range of Intracranial
Translucency in Healthy Turkish
Pregnancies and its Association with First
Trimester Maternal Serum Biochemistry
and Ductus Venosus Pulsatility Index**

**BURCU ARTUNC ULKUMEN, HALIL GURSOY PALA,
YILDIZ UYAR, YESIM BAYTUR,
FAIK MUMTAZ KOYUNCU**

Intracranial translucency (IT) is the translucent appearance of the 4th cerebral ventricle in normal fetuses

In case of neural tube defects (NTD), caudal displacement of the brain results in the compression of the 4th ventricle and loss of the IT image

This finding was the key point for the earlier detection of the spina bifida

For the measurement of IT, the same plane of nuchal translucency (NT) is used: The true mid-sagittal plane should be obtained

The true mid-sagittal plane is seen with the nasal tip anteriorly and the NT posteriorly. The rectangular shape of the palate is seen with the central translucent circle appearance of diencephalon

The appearance of the zygomatic bone is the sign of the rotation of the fetal head which ends up in false plane

Kavalakis I, Souka AP, Pilalis A, Papastefanou I, Kassanos D. [Assessment of the posterior brain at 11-14 weeks for the prediction of open neural tube defects](#). Prenat Diagn 2012;32: 1143-1146.

- The image should be magnified so that only fetal head and upper thorax were included in the image
- IT is bordered with posterior line of the brain stem anteriorly and choroid plexus of the 4th ventricle posteriorly
- In normal fetuses, IT is the third translucent space in mid-sagittal plane: the lowest part represents NT, the second one represents cisterna magna (CM) and the third one is IT

- The normal ranges of IT have been the topic of the recent few studies
- In this study, we aimed to evaluate the normal ranges of IT in a Turkish population and establish the association of the biochemical parameters of 11-14 week screening and also ductus venosus doppler indices with IT measurement

Chen M, Chen H, Yang X, et al. Normal range of intracranial translucency (IT) assessed by three-dimensional ultrasound at 11+0 to 13+6 weeks in a Chinese population. *J Matern Fetal Neonatal Med* 2012;25: 489-492.

Mi-Young Lee, Hye-Sung Won, Ba-Da Jeong, Min-Kyung Hyun, et al. Measurement of intracranial translucency using three-dimensional ultrasound and Volume IT™. *Prenatal Diagnosis* 2012;32: 472-475.

Materials & Methods

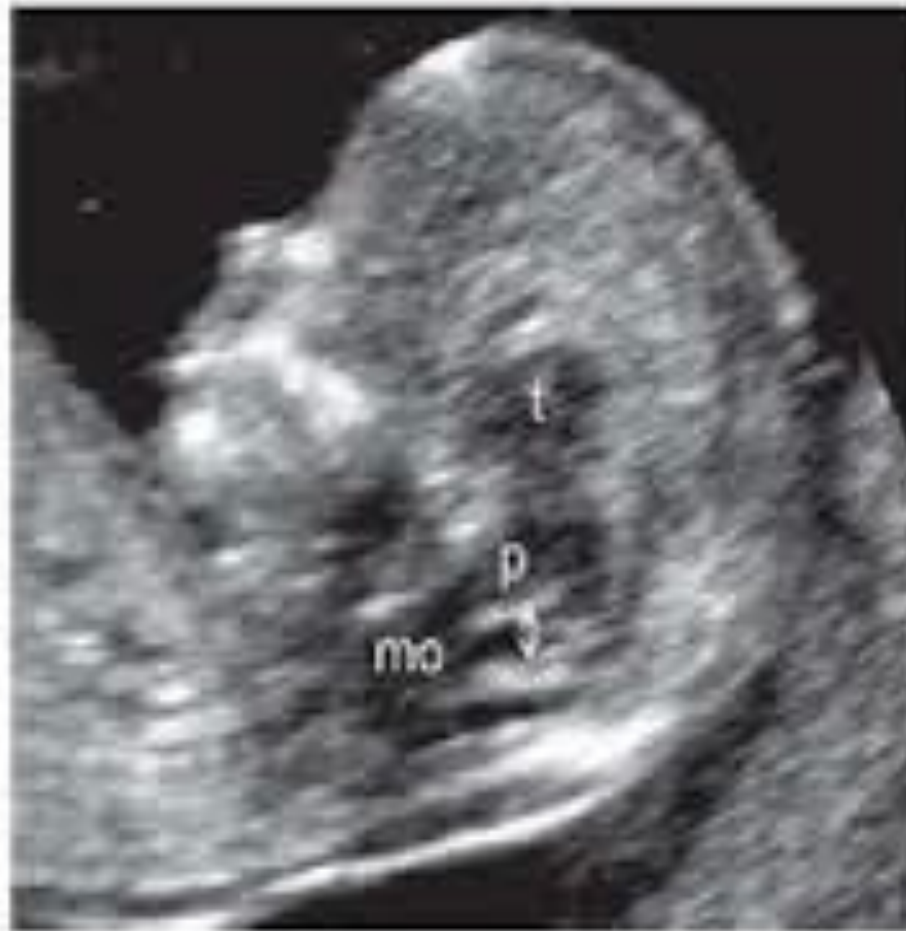- Singleton uncomplicated pregnancies admitted to our perinatology outpatient department for 11 + 0 to 13 + 6 weeks screening
- Approved by the Institutional Ethics Committee and conducted for six month period
- All examinations were carried out via transabdominal probe by two operators (B.A.U. and H.G.P.) accredited with the "Certificate of Competence" for the 11-14 week screening by the Fetal Medicine Foundation (FMF)
- The examinations were carried out by one of the operators, at that time the other operator was observing the fetal planes and measurements independently

Measurement protocol

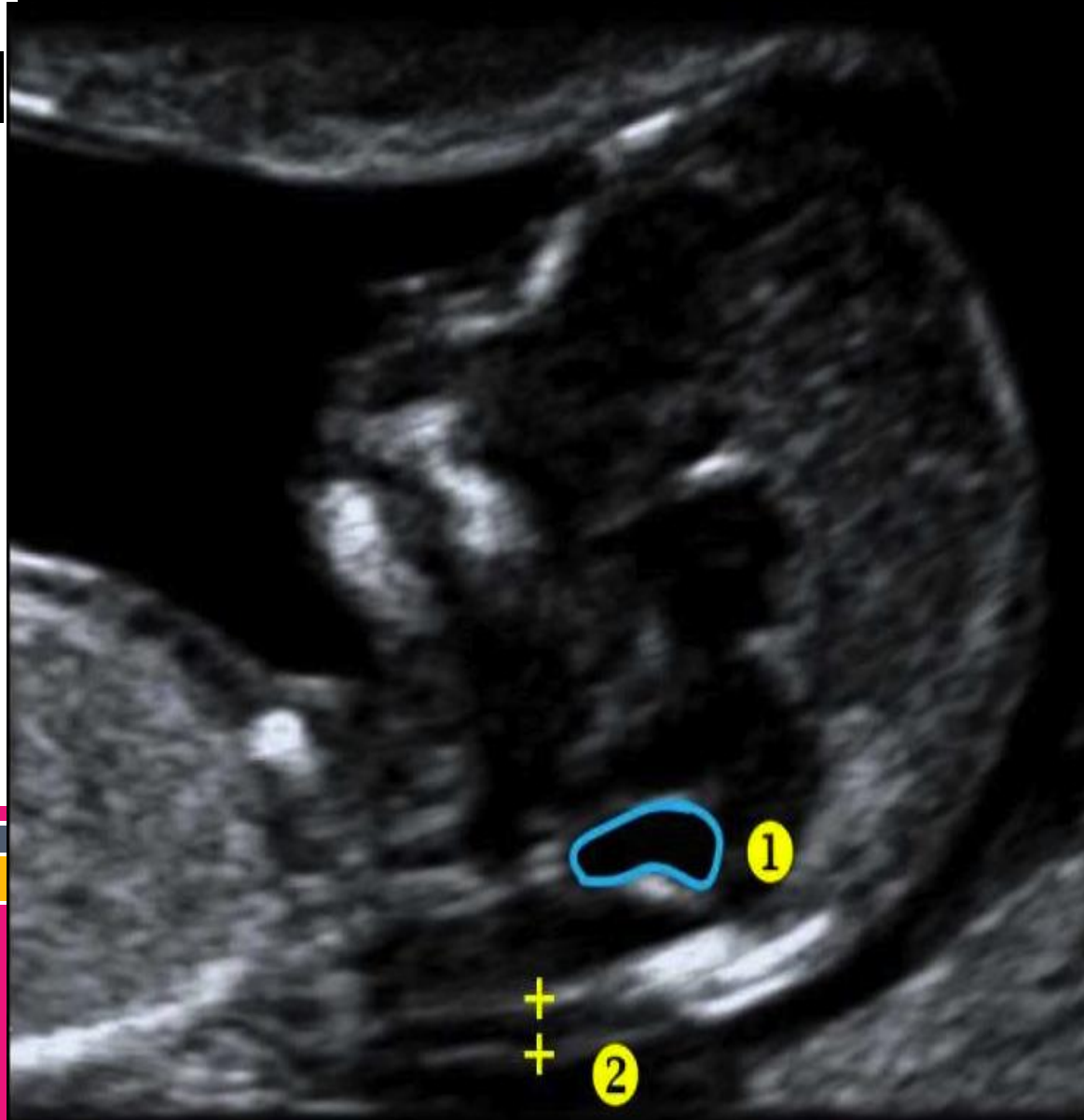
- A Voluson 730 Pro system with a RAB 3,5-MHz array probe (GE Medical Systems, Milwaukee, WI) was used
- The true mid-sagittal plane was confirmed by assessing the presence of the tip of the nose anteriorly, the nuchal membrane posteriorly, the translucent diencephalon and midbrain in the middle, and by showing the rectangular shape of the palate

Measurement and statistical protocol

- IT was measured “in to in” at its widest part
- Two independent measurements were taken and averaged to obtain the final measurement used in the calculations
- Statistical analysis was performed with SPSS for Windows 20.0 software package
- Regression analysis was used to determine the association between IT and NT, pregnancy-associated plasma protein-A (PAPP-A), free β -human chorionic gonadotropin ($f\beta$ -hCG) and CRL length. A p-value of <0.05 was considered statistically significant



- **CRL: 45-84 mm** (11+0 to 13+6 weeks' gestation)
- **Mid-sagittal view** (fetus may either be facing towards or away from the transducer)
- **Landmarks on the profile:** skin over the nasal bridge and the nasal tip (solid arrows)
- **Intracranial structures:** thalamus (t), pons (p), medulla oblongata (mo)
- The **intracranial translucency** (double arrow) is located behind the pons.



- ① IT is usually easily visible at the true mid-sagittal plane of the fetal profile
- ② Nuchal translucency (NT) thickness measurements

1. Telen
Har-high
Pwr 100 %
Gn 1
C7 / M6
P3 / E3

NT
IT



Results

- One hundred and ninety 11-14 week scans were performed during the study period
- The assessment of IT was not possible in 13 cases: resolution of the images was suboptimal, mainly due to abdominal obesity in 7 cases; appropriate fetal position and neutral mid-sagittal plane could not be provided for the remaining 6 cases.
- The assessment rate of IT was 167/190 (87.89 %).

Results

- The mean maternal age was $29,71 \pm 5,43$
- The mean maternal weight was 66.62 ± 11.65 (range: 48.0-105.0)
- The mean CRL length was 63.63 ± 10.05 and mean gestational week was 12.28 ± 0.75
- The mean NT and IT measurements were 1.23 ± 0.43 (range: 0.20-2.68) and $2,29 \pm 0,49$ (range: 0.18-3.80) respectively

Results


- There was no significant correlation between IT with maternal serum PAPP-A MoM ($r = -0.34$, $p = 0.698$) or maternal serum $f\beta$ -hCG MoM ($r = -0.79$, $p = 0.363$), respectively
- There was low- but statistically significant correlation between IT with CRL length ($r = 0.301$, $p = <0.001$), gestational week ($r=0.286$, $p=0.001$) and NT measurement ($r=0.224$, $p=0.007$), respectively
- There was no significant association between IT with ductus venosus doppler pulsatility index ($r=0.108$, $p=0.213$)

Table-1: Descriptive data of the study population

	Mean	Std. Deviation
Maternal weight	66,6222	11,65100
PAPP-A MoM	1,1167	,83361
fβ-hCG MoM	1,3140	,98155
CRL	63,6323	10,05322
Gestational week	12,2857	,75356
NT	1,2341	,42973
IT	2,2983	,49074
Ductus venozus PI	1,1553	,57394

Table-2: Correlation analysis of IT with maternal weight, PAPP-A MoM, f β -hCG MoM, CRL, NT and gestational week

IT	Maternal weight	PAPP-A MoM	f β -hCG MoM	CRL	Gestational week	NT	Ductus Venosus PI
r	0.172	-0.34	-0.79	0.301	0.286	0.224	0.108
p	0.047 *	0.698	0.363	<0.001 *	0.001*	0.007*	0.213

- 
- Our findings showed that IT can be easily measured while scanning for NT.
 - Consistent with recent data, our IT measurements show positive correlation with gestational week and CRL length.
 - Maternal serum biochemistry does not have any effect on IT.
 - Besides, our study highlights that IT is correlated with NT and adds newly to the literature that there is no correlation of IT with ductus venosus pulsatility index.